

# Neuroendocrine tumours

*M T Barakat, K Meeran and S R Bloom*

Department of Metabolic Medicine, Division of Investigative Science, Imperial College London at Hammersmith Campus, Du Cane Road, London W12 0NN, UK

(Requests for offprints should be addressed to S R Bloom; Email: s.bloom@imperial.ac.uk)

## Abstract

Neuroendocrine tumours are a heterogeneous group including, for example, carcinoid, gastroenteropancreatic neuroendocrine tumours, pituitary tumours, medullary carcinoma of the thyroid and pheochromocytomas. They have attracted much attention in recent years, both because they are relatively easy to palliate and because they have indicated the chronic effect of the particular hormone elevated. As neuroendocrine phenotypes became better understood, the definition of neuroendocrine cells changed and is now accepted as referring to cells with neurotransmitter, neuromodulator or neuropeptide hormone production, dense-core secretory granules, and the absence of axons and synapses. Neuroendocrine markers, particularly chromogranin A, are invaluable diagnostically. Study of several neuroendocrine tumours has revealed a genetic etiology, and techniques such as genetic screening have allowed risk stratification and prevention of morbidity in patients carrying the particular mutation. Pharmacological therapy for these often slow-growing tumours, e.g. with somatostatin analogues, has dramatically improved symptom control, and radiolabelled somatostatin analogues offer targeted therapy for metastatic or inoperable disease. In this review, the diagnosis and management of patients with carcinoid, gut neuroendocrine tumours, multiple endocrine neoplasia types 1 and 2, and isolated pheochromocytoma are evaluated.

*Endocrine-Related Cancer* (2004) 11 1–18

## Introduction and definition

The definition of a neuroendocrine cell has changed over the last few years as our understanding and experimental techniques have advanced. In 1969, Pearse proposed the APUD (amine precursor uptake and decarboxylation) classification to describe cells producing polypeptide hormones and biogenic amines identical to those found in neurons (Pearse 1968, 1969). These cells would make up the tightly coordinated diffuse neuroendocrine system, present either in endocrine organs or dispersed throughout the body (Polak & Bloom 1979). The gastroenteropancreatic system alone provides the richest source of regulatory peptides outside the brain (Polak & Bloom 1986a). Indicating a unified origin to these cells, it was originally thought that they all derived from neuroectoderm, but increasingly this was found not to be the case for all neuroendocrine cells (Le Douarin 1988). The following criteria are now generally accepted as defining neuroendocrine cells (Langley 1994): the production of a neurotransmitter, neuromodulator or neuropeptide hormone; the presence of dense-core secretory granules from which the hormones are released by exocytosis in response

to an external stimulus; and the absence of axons and synapses. In practical terms, molecular markers are invaluable in defining neuroendocrine cells, and in particular chromogranin A (Winkler & Fischer-Colbrie 1992, Taupenot *et al.* 2003). More recently, the subtilase proprotein convertases (SPC), particularly SPC2 and SPC3, have been added to the list of useful markers (Bergeron *et al.* 2000). With the discovery of neuroendocrine phenotypes developing in cells such as immunocytes and certain neoplastic cells such as small cell carcinomas, it has recently been proposed that activation of specific genetic switches leading to neuroendocrine phenotypes should also be included in the definition (Day & Salzet 2002).

Neuroendocrine tumours are therefore a very heterogeneous group arising from these neuroendocrine cells, and include carcinoid, non-carcinoid gastroenteropancreatic tumours (such as insulinoma, gastrinoma and VIPoma (VIP, vasoactive intestinal polypeptide)), catecholamine-secreting tumours (pheochromocytomas, paragangliomas, ganglioneuromas, ganglioneuroblastomas, sympathoblastoma, neuroblastoma), medullary carcinoma of the thyroid, chromophobe pituitary tumours,

small cell lung cancer and Merkel cell tumours. The World Health Organization's definition of neuroendocrine tumours is 'morphofunctional' and is primarily based on microscopic characteristics, but incorporates immunohistological data (with such markers as the chromogranins, synaptophysin and non-specific enolase), special stains (e.g. silver), in addition to immunohistochemical stains for specific hormones which result in endocrine hyperfunction syndromes (Solcia *et al.* 2000). For the purposes of this review, the following topics are covered in the vast field of neuroendocrine tumours: etiology, general markers and the specific syndromes related to a limited subset of neuroendocrine tumours, namely carcinoid and other gastroenteropancreatic neuroendocrine tumours, multiple endocrine neoplasia types 1 and 2, and pheochromocytoma.

## Etiology

The genetic predisposition to certain neuroendocrine tumours has generated much interest, particularly with advanced techniques facilitating the identification of mutated genes. Similarly, with analysis of gene expression microarray profiles and multivariate analysis of complex traits (Phillips & Belknap 2002), important information can be used to prognosticate and risk stratify patients. A plethora of genes are known to be involved in neuroendocrine tumorigenesis, including *MEN1*, *RET*, *VHL*, *TSC1* and *TSC2* (Calender 2000), with mutations in *MEN1* remaining the most common form of genetic predisposition to neuroendocrine tumours. Despite the lack of direct evidence, it is likely that neuroendocrine tumorigenesis is similar to that of the well-studied colorectal carcinoma model of a series of multiple genetic alterations leading to activation of oncogenes and/or inactivation of tumour suppressor genes and failure of apoptosis (Fearon & Vogelstein 1990, Shannon & Iacopetta 2001). Intriguingly, the exact sequence of events is crucial for determining the phenotype, as demonstrated by the effect of early loss of *Lkb1* in protection against transformation in Peutz-Jeghers syndrome (Bardeesy *et al.* 2002).

In multiple endocrine neoplasia type 1 (MEN1), germline inactivating mutations in the tumour suppressor *MEN1* gene (chromosome 11q13; Larsson *et al.* 1988) are found in 95% of patients. Somatic mutations of *MEN1* are also found in sporadic cases: 21% of parathyroid adenomas, 33% of gastrinomas, 17% of insulinoma, 36% of bronchial carcinoid, and 50–70% of sporadic thymic and duodenal carcinoid (Jakobovitz *et al.* 1996, Lubensky *et al.* 1996, Emmert-Buck *et al.* 1997, Marx *et al.* 1998, 1999). The absence of detectable mutations in *MEN1* may reflect deficiencies of current technology, or that the inactivation process is via non-mutation mechanisms such

as methylation in the CpG-rich 5'-region of *MEN1*. Indeed, such hypermethylation is found in the *VHL* promoter in von Hippel Lindau (Herman *et al.* 1994, Prowse *et al.* 1997).

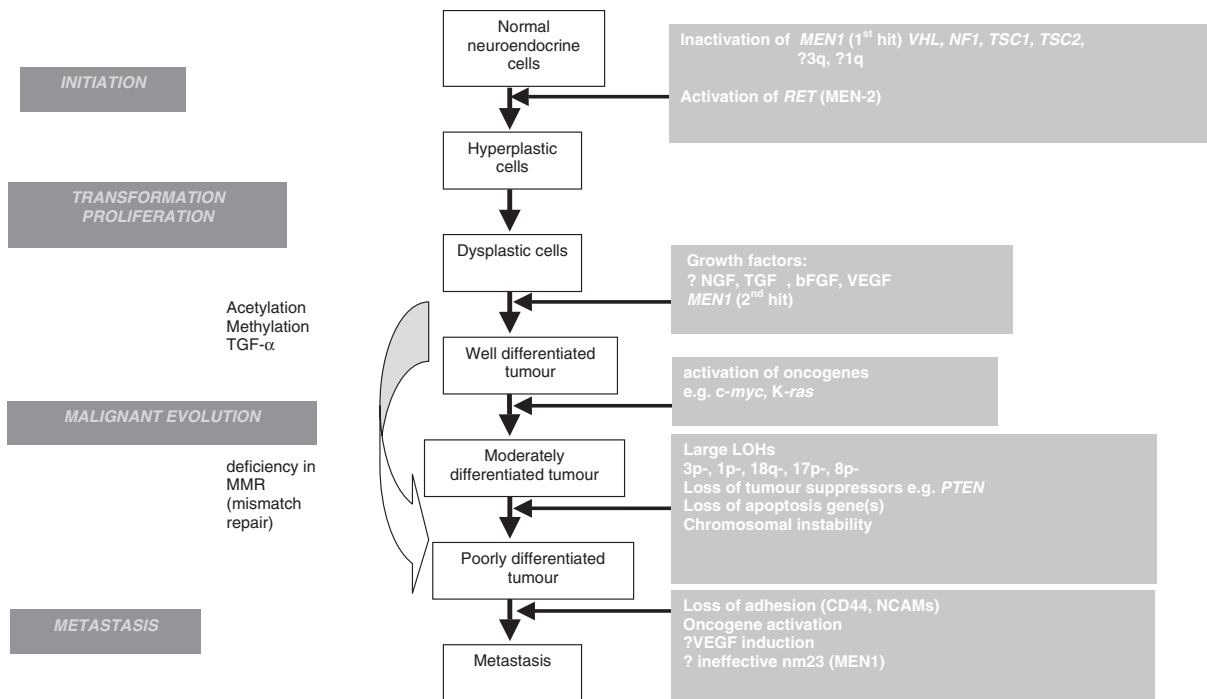
In keeping with Knudson's model (Knudson 1971, Pannett & Thakker 2001), a two-hit process is required for *MEN1* tumorigenesis (Larsson *et al.* 1988, Thakker *et al.* 1989, Bystrom *et al.* 1990). Familial and somatic *MEN1* mutations differ in terms of the former usually presenting with tumour expression at an earlier age, multiple organs affected, and multiple tumours in one organ (Marx *et al.* 1999). Although many mutations have been found in *MEN1*, there seems to be poor genotype-phenotype correlation (Kouvaraki *et al.* 2002). The majority of patients with familial MEN1 will develop non-functioning pancreatic tumours, while 40% will develop gastrinoma, 10% insulinoma and 2% other functioning pancreatic tumours, such as glucagonoma, VIPoma and somatostatinoma (Marx *et al.* 1999).

Based on Fearon and Vogelstein's (1990) genetic model for colorectal tumorigenesis, Fig. 1 illustrates the possible pathways from induction to metastases for neuroendocrine tumours (Calender 2000), including MEN1, MEN2 and pheochromocytoma.

## General markers for neuroendocrine tumours

The group of neuroendocrine tumours can be characterized both by general and specific markers, the most strikingly consistent general markers being the chromogranins. Other general staining markers include pancreatic polypeptide, neuron-specific enolase (NSE), peptide histidine-methionine and human chorionic gonadotrophin subunits (Tapia *et al.* 1981, Hamid *et al.* 1986, Yiangou *et al.* 1987). Chromogranin A (CgA), a secretory granule, is located alongside specific hormones in large dense-core vesicles of neuronal and neuroendocrine cells. Chromogranin B (CgB) is also widely distributed in neuroendocrine cells, although CgA seems to be more widespread (Winkler & Fischer-Colbrie 1992). Staining for the chromogranins in different neuroendocrine tumours is summarized in Table 1 (adapted from Taupenot *et al.* 2003), where CgA seems ubiquitous with the exception of the CgB-staining pituitary lactotrophs and some pancreatic beta-cell tumours.

In one study, plasma CgA was elevated in 94% of endocrine pancreatic tumours, and pancreatic polypeptide in 74% (Eriksson *et al.* 1990). Elevated CgA levels were even more frequent (99%) in malignant carcinoid and gastroenteropancreatic tumours (99%) (Stridsberg *et al.* 1995), with the highest levels seen in metastatic carcinoid (particularly midgut). Plasma CgB (and its 74-amino-acid



**Figure 1** Process of tumorigenesis from initiation to metastatic cancer in neuroendocrine tumours. Based on Calender (2000) and Fearon and Vogelstein (1990). Genes: *MEN1*, multiple endocrine neoplasia type 1; *VHL*, von Hippel Lindau; *NF1*, neurofibromatosis type 1; *TSC1* and *TSC2*, tuberous sclerosis genes 1 and 2; *PTEN*, tumour suppressor gene *PTEN* ('phosphatase and tensin homolog, deleted on chromosome 10'). NGF, nerve growth factor; TGF, transforming growth factor; bFGF, basic fibroblast growth factor; VEGF, vascular endothelial growth factor; NCAM, neural cell adhesion molecule; nm23, tumour metastasis suppressor nm23 (in *MEN1*); LOH, loss of heterozygosity.

fragment termed GAWK) is usually a better marker for benign insulin-producing tumours (Sekiya *et al.* 1989, Yasuda *et al.* 1993). Finally, multiple hormones may be secreted by some tumours (Wood *et al.* 1983), and up to 62% have elevated gastrin despite only 30% presenting with peptic ulcer disease.

## Specific syndromes

### Carcinoid and other gut neuroendocrine tumours

Over the last few years, a new classification of neuroendocrine gastroenteropancreatic tumours (GEPs) has been developed based on clinicopathologic features (Capella *et al.* 1994, Kloppel & Heitz 1994, Rindi *et al.* 1998). Tumours are termed functioning neuroendocrine tumours according to their leading clinical and endocrine profile, while those without plasma hormone elevation and lacking endocrine symptoms are labelled non-functioning neuroendocrine tumours (Taheri & Meeran 2002). In excess of 50% of neuroendocrine tumours are of the 'carcinoid' type, with the remainder being mostly pancreatic and including insulinomas, gastrinomas, VIPomas and glucagonomas.

Although these two categories differ in specific histology and location, there are many diagnostic and therapeutic similarities between them, and these will be covered in the sections below. In general, neuroendocrine tumours are slow-growing. The classification into benign and malignant depends on various features summarized in Table 2 (Rindi *et al.* 1998).

### Carcinoid

Mostly derived from serotonin-producing enterochromaffin (EC, or Kulchitsky's) cells, these tumours termed 'carcinoid' have a wide clinical spectrum of presentation and symptomatology (McStay & Caplin 2002). Indeed, it is felt by some that the term should be made archaic because of this wide spectrum (Gilligan *et al.* 1995). Fewer than 10% of patients with carcinoid suffer from the classical carcinoid syndrome of flushing, hypotension, diarrhoea, wheezing and heart disease. These symptoms seem to be related directly to serotonin levels (elevated in 93–94% of 600 patients with carcinoid syndrome), although serotonin can still be elevated in asymptomatic individuals (elevated in 25–30% of 7000 asymptomatic patients) (Vinik 2001). High serotonin levels seem to predict the development of carcinoid heart disease (Moller

**Table 1** Detection of granins in neuroendocrine tumours. Adapted from Taupenot *et al.* (2003).

	Chromogranin A	Chromogranin B	Secretogranin III
Carcinoid	+	+	+
Gastrinoma	+	+	ND
Glucagonoma	+	+	+
Insulinoma	+	+	+
PPoma	+	ND	ND
Somatostatinoma	+	ND	ND
VIPoma	+	ND	ND
Non-functioning islet cell carcinoma	+	ND	ND
Corticotrophinoma	+	+	+
Gonadotrophinoma	+	+	+
Somatotrophinoma	+	+	+
Thyrotrophinoma	+	+	+
Prolactinoma	–	+	+
Non-functioning pituitary adenoma	+	+	+
Phaeochromocytoma	+	+	+
Parathyroid adenoma	+	+	+
Ganglioneuroblastoma	+	ND	ND
Ganglioneuroma	+	ND	+
Neuroblastoma	+	+	+
Medulloblastoma	+	ND	ND
Paraganglioma	+	+	+
Medullary thyroid carcinoma	+	+	+
Prostate tumour with neuroendocrine differentiation	+	+	+
Breast tumour with neuroendocrine differentiation	+	+	+

ND, not detected.

*et al.* 2003). Other carcinoid tumours deriving from the gastric histamine-secreting enterochromaffin-like (ECL) cells produce an ‘atypical’ carcinoid syndrome. These tumours, which have low serotonin levels, frequently secrete the serotonin precursor 5-hydroxytryptophan (5-HTP). This produces the ‘atypical’ symptoms seen in foregut carcinoids with more intense and protracted purplish flushing; the limbs as well as the upper trunk are often affected and frequently result in telangiectasia (Snow *et al.* 1955, Sandler & Snow 1958, Vinik 2001).

From the most recent and largest US epidemiology series (using the 1992–1999 cohort), the age-adjusted incidence of carcinoid tumours varies between 2.47 and 4.48 per 100 000 population, with the rates being highest

in black males, then black females, then white Americans (Modlin *et al.* 2003). In this series, the population-corrected male-to-female ratio for all carcinoid sites was 0.86, and the average age at diagnosis for all carcinoids was 61.4 years (compared with 63.9 years for non-carcinoid tumours). Table 3 summarizes the frequency of carcinoid at different sites (most occurring in the gut at 67.5%, then the lung at 25.3%), with the associated 5-year survivals. Predisposition to metastatic spread depends on location and size (Lauffer *et al.* 1999, Modlin *et al.* 2003).

In addition to the general markers mentioned above, the specific markers for carcinoid include urinary 5HIAA, neuropeptide K, substance P and other tachykinins. Urinary 5-hydroxyindole acetic acid (5HIAA) and neuropeptide K show high sensitivity in midgut carcinoid, with less diagnostic usefulness in foregut and hindgut carcinoid (Janson *et al.* 1997). If a diagnosis of carcinoid is suspected with normal baseline urinary testing, the pentagastrin test with measurements of plasma tachykinins is helpful (Norheim *et al.* 1986).

*Non-carcinoid gastroenteropancreatic neuroendocrine tumours*

Most of the non-carcinoid gastroenteropancreatic neuroendocrine tumours arise in the pancreas. Making up less

**Table 2** The proposed classification into benign, uncertain and malignant gastroenteropancreatic tumours (Rindi *et al.* 1998).

Tumour characteristic	Benign	Uncertain	Malignant
Size of tumour (cm)	≤2	> 2	> 2
Local spread	No	Yes	Yes
Vascular invasion	No	Yes	Yes
Nuclear atypia	No	Yes	Yes
Gross invasion	No	No	Yes
Metastases	No	No	Yes

**Table 3** Carcinoid tumours – relation between site, metastatic potential and 5-year survival. Data from the 1992–1999 cohort (Modlin *et al.* 2003).

Site	% of all carcinoids	Regional metastases (%)	Distant metastases (%)	5-year survival with no metastases (%)	5-year survival with regional metastases (%)	5-year survival with distant metastases (%)
Lung	25.3	5.2	0.5	81.1	76.7	25.6
Small intestine	28.2	35.9	22.4	59.9	72.8	50
Appendix	2.4	28.9	9.9	80.8	88.1	9.6
Colon	7.6	25.8	29.5	76	71.6	30
Rectum	18.5	2.2	1.7	90.8	48.9	32.3
Stomach	5.9	3.1	6.5	69.1	N/A	21.2
Ovary	1.4	5.2	0.5	90.9	N/A	28.3

N/A, not available.

than half of all neuroendocrine tumours and only 1–2% of all pancreatic tumours, pancreatic neuroendocrine tumours (PET) form an important group with a better prognosis than non-neuroendocrine tumours. Deriving from the diffuse neuroendocrine system of the gut (Polak & Bloom 1986a), PETs were formerly classified as APUDomas (tumours of the amine precursor uptake and decarboxylation system), and can secrete a vast number of hormones depending on the cell of origin. Physiologically, these hormones are involved in an intricate network of autocrine, paracrine, endocrine and neurotransmitter communication.

Although the annual incidence of PETs is approximately 3.5 to 4 per million population, post-mortem data suggests a much higher incidence. Indeed they have been detected in 0.3% to 1.6% of unselected autopsies in which only a few sections of pancreas were examined, and in up to 10% of autopsies in which the whole pancreas was systematically inspected (Kimura *et al.* 1991).

Depending on whether secreted hormone is detectable and associated symptoms are present, gastroenteropancreatic neuroendocrine tumours (GEPs) can be divided into 'functioning' and 'non-functioning' tumours. The 'functioning' tumours may secrete several peptides, only some of which may produce symptoms. Similarly, a tumour which originally secreted one peptide may de-differentiate to co-secrete other peptides. Typically, these tumours are slow-growing, and often morbidity is from the secreted hormone (or hormones) rather than tumour bulk. The presence of a specific endocrine hyperfunction syndrome seems to be as important as purely pathological features for predicting tumour behaviour (Kloppel & Heitz 1988, Solcia *et al.* 1990) (see Table 4 taken from data from Aldridge & Williamson 1993, Arnold *et al.* 2000, Schindl *et al.* 2000, Jensen 2001, Taheri *et al.* 2001). In the case of 'non-functioning tumours', it is accepted that there may be secreted, but as yet undetectable, peptides. These non-functioning tumours tend to be more

aggressive and often present after metastasizing with symptoms of tumour bulk (Legaspi & Brennan 1988).

The following are specific markers for functioning non-carcinoid GEPs: fasting hormones such as gastrin, glucagon, pancreatic polypeptide, somatostatin, neurotensin, and vasoactive intestinal polypeptide (VIP), and random parathyroid hormone-related peptide levels (PTHrP) (with simultaneous calcium and parathyroid hormone (PTH) measurements). In the case of gastrin, the patient has to be off proton pump inhibitors for at least two weeks and off H<sub>2</sub>-blockers for at least three days. Caution, however, is required if the clinical likelihood of gastrinoma is high, since there is a high risk of peptic ulcer perforation when medical therapy is stopped for the gastrin test. Even on proton pump inhibitors, very high gastrin levels (> 500 pg/ml or > 250 pmol/l) are indicative of gastrinoma, and repeat testing off therapy should not be recommended (Ashrafian *et al.* 2002). Differential diagnoses, which include atrophic gastritis, hypercalcaemia and renal impairment, may be excluded by measuring basal acid output: spontaneous basal acid outputs of 20 to 25 mmol/h are almost diagnostic and > 10 mmol/h suggestive. If the test results are equivocal, the secretin test is helpful: a rise of gastrin (instead of the normal fall) in response to intravenous secretin of greater than 200 pg/ml (100 pmol/l) has a sensitivity of 80–85% for gastrinoma (McGuigan & Wolfe 1980, Frucht *et al.* 1989).

The dynamic test for the diagnosis of an insulinoma is a three-day fast, allowing unlimited non-caloric fluids (Service 1995, Service & Natt 2000). Elevated plasma insulin and C-peptide levels are diagnostic in the presence of hypoglycaemia (glucose below 2.2 mmol/l (40 mg/dl)), and this is achieved by 48 h of the fast in > 95% of insulinomas (Friesen 1987). If no hypoglycaemia is achieved by the end of the fast, the sensitivity can be further increased by exercising the patient for 15 min. The fast is terminated after the exercise period, or prior to this if hypoglycaemia is achieved, with simultaneous plasma

9

**Table 4** Tumour syndromes of gastrointestinal neuroendocrine tumours (NET). Adapted from Aldridge & Williamson (1993), Arnold *et al.* (2000), Jensen (2001), Schindl *et al.* (2000) and Taheri *et al.* (2001). The percentage with MEN1 of each tumour is independent of family history.

Tumour	Frequency of pancreatic neuroendocrine tumours (%)	Tumour location	% with MEN1	Malignancy (%)	Clinical syndrome
Insulinoma	70–75	Pancreas > 99%	4–5	<10	Hypoglycaemia Weight gain
Gastrinoma	20–25	Duodenum 70% Pancreas 25%	20–25	> 50	Abdominal pain Diarrhoea Peptic ulceration
VIPoma	3–5	Pancreas 90%	6	> 50	Secretory diarrhoea Hypokalaemia Achlorhydria Metabolic acidosis Flushing
Glucagonoma	1–2	Pancreas 100%	1–20	> 70	Necrolytic migratory erythema Diabetes Cachexia Thromboembolic disease
PPoma	<1	Pancreas 100%	18–44	> 60	Pain Weight loss Diarrhoea
Somatostatinoma	<1	Pancreas 55% Duodenum + jejunum 44%	45	> 50	Steatorrhoea Diabetes Gallstones Weight loss
Carcinoid	<1 mostly extrapancreatic	Midgut 75–87% Foregut 2–33% Hindgut 1–8% Unknown 2–15%	Rare	90	Classical carcinoid Flushing Diarrhoea Wheeze Cardiac fibrosis Pellagra dermatosis
Corticotrophinoma	<1	Pancreas 4–14% (of all ectopic ACTH)	Rare	> 99	Cushing's syndrome Pigmentation
CRFoma	<1	Pancreas	Rare	> 99	Hypercalcaemia Nephrolithiasis Nephrocalcinosis Osteoporosis
PTHrPoma	<1	Pancreas	Rare	> 99	Diarrhoea, flushing Acromegaly
Calcitoninoma	<1	Pancreas	16	> 80	
Somatotrophinoma	<1	Pancreas 30% Lung 54% Jejunum 7%	16	50	
“Non-functioning”	<1	Pancreas + gastrointestinal tract	18–44	> 80	Symptoms of tumour bulk Weight loss

PPoma, pancreatic polypeptide secreting tumour; CRF, corticotrophin releasing factor.

**Table 5** Imaging modalities for gastroenteropancreatic neuroendocrine tumours.

Somatostatin- receptor- scintigraphy	Sensitivity 90% (excluding insulinoma) Specificity 80% (excluding insulinoma) Sensitivity 10–50% for insulinoma
CT	Useful preoperatively for localizing tumours, but difficulty detecting tumours <1 cm Sensitivity of 29% in one study for detecting pancreatic insulinoma compared with endoscopic ultrasound
Endoscopic ultrasound of pancreatic neuroendocrine tumours	Sensitivity 80–90% Most sensitive for detecting insulinomas (94%) Smallest lesion detectable 5 mm in pancreatic head Lower sensitivities for extrapancreatic tumours (50%)
Visceral angiography	Helpful for subcentimetre tumours, where a tumour blush is seen Furthermore, can be combined with calcium stimulation in individual pancreatic arteries with venous sampling from the hepatic vein (see text for details)
MRI	In general no more helpful than CT
Positron emission tomography with 11C-serotonin precursor 5-HTP instead of 18F-deoxyglucose	Selective uptake in carcinoid with high resolution allowing liver and lymph node lesion detection
Intraoperative ultrasound for pancreatic tumours	Additional invaluable information for the surgeon operating on the delicate pancreas
Intraoperative gamma probes with somatostatin analogue (111InDTPA-D-Phe1)-pentetreotide tracer	Recently introduced, allows detection of lesions <5 mm and identified 57% more lesions than the “palpating finger”
MIBG for gastroenteropancreatic neuroendocrine tumours	Very few gastroenteropancreatic tumours take up MIBG, since they derive from endoderm and not neuroectoderm

and urine samples for sulphonylurea analysis, which must be shown to be negative for the diagnosis of insulinoma (Todd & Bloom 2002). Finally, the reader needs to be aware of the various insulin assays: the competitive and increasingly used two-site noncompetitive immunoassays. The main problems relate to the variable specificity, with some detecting proinsulin, the interference from insulin-degrading enzymes in haemolysed samples and the presence of anti-insulin antibodies (Sapin 2003)

#### *Radiological localization of carcinoid and other gut neuroendocrine tumours*

The Delphi consensus has recently been published for standardizing the diagnostic imaging of neuroendocrine tumours (Ricke *et al.* 2001). Somatostatin receptor scintigraphy (SRS) forms the mainstay of imaging techniques, with a sensitivity of up to 90% and specificity of 80% (Krenning *et al.* 1993, Lebtahi *et al.* 1997, Termanini *et al.* 1997, Kwekkeboom & Krenning 2002), although only 10 to 50% of insulinomas are SRS-positive (Modlin & Tang 1997, Warner & O’дорисіо 2002). Table 5 summarizes the different modalities and their usefulness, including computed tomography (CT), endoscopic ultrasonography (EUS) (Lightdale *et al.* 1991, Glover *et al.* 1992, Palazzo *et al.* 1992, Rosch *et al.* 1992, de Kerviler *et al.* 1994, Thompson *et al.* 1994, Ruzniewski *et al.* 1995, Zimmer *et al.* 2000), positron emission tomography

(Eriksson *et al.* 2000, 2002, Warner & O’дорисіо 2002), intraoperative ultrasound and intraoperative gamma probes with the tracer (111In DTPA-D-Phe1-pentetreotide (Adams & Baum 2000). Given that GEPs derive from endoderm and not catecholamine-producing neuroectoderm, there is little place for <sup>131</sup>I-metaiodobenzyl-guanidine (MIBG) in GEP imaging (European Neuroendocrine Tumour Network (ENET) 2000).

With pancreatic tumours, the surgeon requires as much information regarding location as possible. Selective angiography with secretagogue injection into the main pancreatic arteries allows biochemical in addition to angiographic localization. In this procedure, the main pancreatic arteries (gastroduodenal, superior mesenteric, inferior pancreaticoduodenal and splenic) are cannulated separately and examined for a tumour blush. A secretagogue (calcium has taken the place of secretin; Turner *et al.* 2002) is injected into each of these arteries individually, and venous samples are collected from the hepatic vein for biochemical analysis of the suspected hypersecreted hormone (e.g. gastrin or insulin). In the presence of a tumour, the hormone levels double after 30 s, whereas the normal effect is a reduction in levels (Doppman *et al.* 1990, 1991, Fedorak *et al.* 1993, Goldstone *et al.* 1996, O’Shea *et al.* 1996). The tremendous advantage of this technique is that it allows biochemical localization of the tumour (e.g. a very small insulinoma) even if the radiology appears

**Table 6** The specific medical treatments for some neuroendocrine tumour syndromes.

Hypersecretion syndrome	Medical therapy
Carcinoid	Somatostatin analogue for SRS positive carcinoid Interferon- $\alpha$ for SRS negative carcinoid Histamine antagonists (H1 and H2) Cyproheptadine, nicotinamide
Insulinoma	Frequent slow-release complex carbohydrate intake Guar gum Diazoxide Intravenous dextrose if period of fasting Somatostatin analogue if SRS positive (usually malignant)
Gastrinoma	High dose proton pump inhibitor (life-long in patients with MEN1, since high recurrence rate with surgery)
Glucagonoma	High dose somatostatin analogue Anticoagulation since associated with thrombophilia Insulin for diabetes mellitus
VIPoma	High dose somatostatin analogue Aggressive intravenous rehydration in acute attack of diarrhoea Potassium + bicarbonate in acute attacks
Somatostatinoma	Pancreatic enzyme supplementation Insulin for diabetes mellitus
PTHrPoma	High dose somatostatin analogue Intravenous rehydration Bisphosphonates for often life-threatening hypercalcaemia Somatostatin analogue
Non-functioning	Somatostatin analogue if SRS scan positive and progressive disease

normal. Furthermore, with MEN1, different tumours may co-exist, and this technique will help to distinguish them biochemically. Finally, and perhaps the procedure's greatest advantage is that it allows the detection of liver metastases, since the hepatic artery is always cannulated at the end of the procedure and a rise in hormone levels detectable in the hepatic vein after calcium injection into the hepatic artery is diagnostic of liver metastases.

### Medical treatment

Until curative surgical treatment is performed, or if surgery is not indicated, medical treatment has to be initiated for symptom control. Table 6 summarizes the medical treatments for the various hypersecretion syndromes. The greatest impact for control of symptoms has been afforded by the somatostatin analogues in SRS-scan positive tumours, and it is known that somatostatin immunoreactivity is often found in neuroendocrine tumours (Polak & Bloom 1986b). There are five somatostatin receptors (sstr1–5), but the longer-acting analogues, lanreotide and octreotide, bind preferentially to sstr2 and to a lesser extent to sstr5 (Patel & Srikant 1994, Reisine & Bell 1995, de Herder & Lamberts 2002). The effectiveness of these analogues at reducing hormone production and tumour stabilization (Arnold *et al.* 1996, di Bartolomeo *et al.* 1996, Eriksson

*et al.* 1997, Faiss *et al.* 1999) has been attributed to the sstr2 receptor (Patel & Srikant 1994, Buscail *et al.* 1995, Reisine & Bell 1995, Wulbrand *et al.* 1998). Given the low sensitivity of SRS imaging for insulinomas, it is not surprising that only 50% of insulinomas express sstr2 (Wulbrand *et al.* 1998), and it therefore follows that long-acting somatostatin analogues benefit only those with sstr2-positive tumours. In 'non-functioning' tumours, somatostatin analogues are beneficial where the SRS scan is positive and there is evidence of tumour progression or high mitotic rate (European Neuroendocrine Tumour Network (ENET) 2000). An exciting prospect in this field is the development of new somatostatin analogues that have differing specificities to the various somatostatin receptors, improving their therapeutic effectiveness in tumours that lack, for instance, sstr2. Until these are available, for progressive SRS-negative (i.e. sstr2/5 negative) carcinoid tumours, interferon-alpha should be the treatment of choice.

### Interferon-alpha and chemotherapy for gut neuroendocrine tumours

Interferon-alpha has been used in the treatment of carcinoid for some time (Obergh *et al.* 1983) to control hormone secretion, symptoms and tumour growth. Many trials looking at its effectiveness in malignant and mostly

**Table 7** Non-medical treatment options for gastroenteropancreatic neuroendocrine tumours.

Non-medical treatment	Effectiveness
Curative surgery	Best option if feasible
Resection of primary	Often pancreatic insulinomas can be enucleated easily
Resection of resectable liver metastases	70–80% 4–5 year survival with curative surgery
Liver transplantation	In highly selected cases can improve survival
Hepatic arterial embolization	Most effective for liver metastases from functioning neuroendocrine tumours producing symptoms. Significant reduction in symptoms (40–90%)
Chemotherapy with hepatic arterial occlusion	Difficult to compare with other treatments owing to lack of randomized trials and different patient groups
Hepatic chemoembolization	Hepatic arterial occlusion with local cytotoxic chemotherapy. Only palliative but has good symptomatic responses (63%)
Hepatic radioembolization	Hepatic artery occlusion with radio-isotope microspheres (brachyradiotherapy). Limited experience with this as yet
Hepatic cryosurgery	Placement of cryoprobes into each metastasis. Useful for palliation, but only when <40% of liver is infiltrated
Palliative surgery	Shown to provide an average of 6 months symptom relief but only when >90% tumour resected (63% 5-year survival)
Radio-labelled somatostatin analogues	Most exciting development in the field of neuroendocrine tumours. Large multi-centre trials are currently running, with encouraging initial reports of tumour regression (10%) as well as symptom relief

carcinoid neuroendocrine tumours have been published (Obergh 2000). In the largest studies, interferon-alpha showed a 42% biochemical and 14% tumour response in carcinoid, and a 51% biochemical and 12% tumour response in neuroendocrine pancreatic tumours (Obergh & Eriksson 1991, Eriksson & Obergh 1993). Side-effects, however, are not insignificant and include flu-like symptoms in 89%, weight loss in 59%, fatigue in 51% and depression in 50%. There is also a risk of hepatotoxicity, autoimmune disorders and the development of neutralizing antibodies. It is useful to note that in a recent prospective randomized trial using interferon-alpha alone, somatostatin analogue alone, or the combination showed no additional benefit of the combination over the monotherapies (Faiss *et al.* 2003).

In slow growing, well-differentiated neuroendocrine tumours (NETs), where tumour growth <25% in 1 year, chemotherapy has limited benefit, and other treatment modalities should be given priority in a multidisciplinary approach. Chemotherapy should be considered for the faster-growing metastatic tumours, and has response rates of 20 to 69% (Rougier & Mitry 2000). Indeed, in undifferentiated NETs, the chemosensitivity is similar to that of small cell carcinoma of the lung. Various combinations of chemotherapy have been used, including streptozotocin and adriamycin in well-differentiated pancreatic NETs (Moertel *et al.* 1992), lomustine (CCNU) and 5-fluorouracil (5FU) in advanced NETs (Kaltsas *et al.* 2002), etoposide (VP16) and cisplatin (CDDP) (Moertel *et al.* 1991, Fjallskog *et al.* 2001) in poorly-differentiated, aggressive NETs giving response rates of 50 to 56% and

benefitting pancreatic NETs and foregut carcinoids most. However, toxicity rates were high.

#### *Surgical treatment of carcinoid and other gut neuroendocrine tumours*

In general, curative surgical resections of the primary should be attempted if surgically feasible, even if the tumour size is small and slow-growing, since the secreted hormones may cause significant morbidity and potential mortality (e.g. small insulinoma). Increasingly now, surgeons are even attempting curative surgery of metastases when confined to the liver and where there is sufficient hepatic reserve (Que *et al.* 1995, Chen *et al.* 1998, Chamberlain *et al.* 2000, Jaeck *et al.* 2001, Yao *et al.* 2001), with 4–5 year survival between 70–85%. Outcomes were best with previous resections of the primary tumour and with fewer than 5 liver lesions (Yao *et al.* 2001). In selected patients with numerous liver metastases, liver transplantation has been performed, with survival of 52% after 1 year (Bechstein & Neuhaus 1994).

Surgery also has a place in palliation, where tumour bulk is too extensive for curative resections. In one study, the estimated 5-year survival was 63% with palliative resections (Chamberlain *et al.* 2000). Cryosurgery, where a cryoprobe is inserted surgically into each metastasis causing tumour necrosis, has been used in palliation of liver metastases where less than 40% of the liver is affected. In a small series, symptoms were relieved for a median time of 12 months (Bilchik *et al.* 1997). A rigorous comparison with other treatment modalities is required to assess the overall benefit of cryosurgery, particularly on survival.

### *Treatment with interventional radiology*

Numerous non-medical treatment modalities for gastrointestinal NETs are available (summarized in Table 7). For symptomatic control, hepatic arterial embolization with polyvinyl alcohol microspheres (150–500  $\mu\text{m}$  diameter) is very effective in metastatic pancreatic NETs and carcinoid with benefit in 40 to 90% of patients for a median duration of 10 to 15 months (Carrasco *et al.* 1983, Ajani *et al.* 1988, Eriksson *et al.* 1998). This procedure, however, needs operator expertise and stringent adherence to formal hospital pretreatment protocols of intravenous methylprednisolone, meticulous fluid balance, intravenous octreotide, aprotinin, broad-spectrum antibiotics and oral allopurinol. In addition, oral cyproheptadine and nicotinamide are required for carcinoid, and dextrose infusions for insulinomas. These precautions are to minimize the high complication rate, where hepatic abscess, renal failure, intestinal and cholecystic necrosis can occur in up to 10% of patients with a mortality of 3 to 7%. When beneficial in individual patients, the procedure can be repeated several times as symptoms recur. Some centres have combined hepatic embolization with systemic chemotherapy using 5FU–streptozotocin alternating with adriamycin–dacarbazine to some additional benefit (Moertel *et al.* 1994), although the patient groups were different, making direct comparisons difficult.

Chemoembolization is where the hepatic arterial injection is with local cytotoxic chemotherapy, which has given response rates of 63% for symptoms and mean survival of 2 years (Stokes *et al.* 1993, Wallace *et al.* 1996, Ruzniewski & Malka 2000). When compared with curative hepatic resections, it provided a median survival from treatment of 32 months and an actuarial 5-year survival of 40% (Yao *et al.* 2001). Finally, the procedure of radioembolization has been attempted for hepatic metastases of NETs, where microspheres labelled with radio-isotope (for example yttrium 90) are used to occlude the hepatic arterial branches supplying the metastases. This form of brachyradiotherapy remains experimental, and further experience is awaited (Andrews *et al.* 1994).

### *Targeted therapy with radio-labelled somatostatin analogues*

Perhaps the most exciting development in the therapeutic armamentarium against metastatic or inoperable NETs has been the introduction of targeted therapy with radio-labelled somatostatin analogues for SRS-scan positive tumours. Various trials are currently underway to assess efficacy, but initial results are very encouraging. Compounds such as (111)In-DTPA-D-Phe1-octreotide (Tiensuu *et al.* 1999), 90-yttrium-DOTA-D-Phe1-Tyr3-octreotide (de Jong *et al.* 1997), (177)Lu-DOTA(0), Tyr3-octreotate (Kwekkeboom *et al.* 2003) and 90-

yttrium-DOTA-lanreotide (Leimer *et al.* 1998, Virgolini *et al.* 2002) have been used. In the phase IIa MAURITIUS study (Virgolini *et al.* 2002), 90-yttrium-DOTA-lanreotide in 70 patients with SRS-scan positive tumours resulted in stable disease in 35% and regression in 10%. This field is currently attracting much attention as further results are made available.

### **Multiple endocrine neoplasia type 1 (MEN1)**

A consensus statement giving guidelines for the diagnosis of MEN has recently been published (Brandi *et al.* 2001). It was agreed that no simple definition for MEN1 existed, but a practical definition was the presence of two of the three main MEN1-related tumours (parathyroid adenomas, enteropancreatic endocrine tumours and pituitary tumours). Familial MEN1 was defined as at least one MEN1 case with one first degree relative with one of the three MEN1-related tumours. Table 8 lists the features of MEN1.

The genetic test for the *MEN1* (menin) gene mutation (11q13) is indicated in index cases and asymptomatic relatives. However, no mutation is found in 10 to 20% of index cases for familial MEN1, probably reflecting mutations in untested parts of the *MEN1* gene or deficiencies in PCR amplification methods. Screening for tumour expression in a patient with or suspected of having the *MEN1* mutation should take place from the age of 5 years for anterior pituitary tumours (prolactin, insulin-like growth factor-I, MRI) and insulinomas (fasting glucose, insulin and three-day fast), age of 8 years for parathyroid adenomas (calcium, PTH), and age of 20 for enteropancreatic tumours (chromogranin A, fasting gut hormones, octreotide scan, CT) and foregut carcinoid (endoscopy, CT). Some centres advocate the standardized meal stimulatory test with measurements of pancreatic polypeptide and gastrin (Oberg & Skogseid 1998). The response is abnormal in pancreatic endocrine tumours with a 75% sensitivity in individuals whose mean age was 25 years. Furthermore, the test was useful in differentiating between the high gastrin seen in achlorhydria and gastrinoma.

As tumours arise in patients with MEN1, morbidity results primarily from hormone secretion (e.g. PTH, insulin, gastrin, growth hormone) and also from tumour bulk (e.g. pituitary tumours compressing the optic chiasm, non-functioning pancreatic tumours with liver metastases). The consensus statement regarding the management of these tumours (Brandi *et al.* 2001) is as follows: subtotal parathyroidectomy for hyperparathyroidism, surgical resection of pancreatic neuroendocrine tumours where surgically feasible except for gastrinoma where recurrence is high post surgery in MEN1 and where some advocate non-surgical therapy, and management of

**Table 8** Tumours associated with MEN1, with estimated penetrance at age 40. Adapted from Brandi *et al.* (2001).

MEN1 tumours	Penetrance at age 40 (%)	Speculated frequency of germline <i>MEN1</i> mutations presumed to be sporadic from family study (%)
Parathyroid adenoma	90	1
Enteropancreatic tumour		
Gastrinoma	40	5
Insulinoma	10	
PPoma	20	
Glucagonoma, VIPoma, somatostatinoma	2	
Non-functioning (often incidental finding)	nearly 100	
Anterior pituitary		
Prolactinoma	20	1
Somatotrophinoma + prolactinoma	5	
Somatotrophinoma	5	
Non-functioning	5	
Corticotrophinoma	2	
Thyrotrophinoma	rare	
Foregut carcinoid		1
Thymic carcinoid	2	
Bronchial carcinoid	2	
Gastric carcinoid	10	
Adrenal cortex (non-functioning) tumour	25	
Lipomas	30	0.1
Facial angiofibromas	85	1
Collagenomas	70	
Ependymoma	1	
Phaeochromocytoma	<1	

pituitary tumours in a similar way to sporadic cases. There has been a comprehensive recent review of the latter (Arafah & Nasrallah 2001).

### Multiple endocrine neoplasia type 2 (MEN2)

MEN2 and all its variants (including familial medullary carcinoma of the thyroid, FMTC) are autosomal dominant syndromes resulting from germline mutations in the *RET* gene (10cen-10q11.2). In all variants, there is a high penetrance (90%) of medullary carcinoma of the thyroid (MTC); the likelihood of *RET* germline mutations in a patient with apparently sporadic MTC is 1 to 7% (Eng *et al.* 1995). The clinical features are summarized in Table 9. The criteria for *RET* mutation testing (Brandi *et al.* 2001) should be as for *MEN1* (noted above) and is mandatory in all children at 50% risk, to facilitate prophylactic thyroidectomy in positive cases. In MEN2, there is the added advantage that 98% of MEN2 index cases have an identified *RET* mutation, and only a limited number of mutations exist, involving exons 10, 22, 13, 14, 15 and 16. If testing these exons yields no mutation, then the remaining 15 exons should be sequenced (currently available in research laboratories). Tumour tissue testing

for somatic *RET* mutations in sporadic MTC or sporadic phaeochromocytoma is generally not indicated.

The screening for tumour expression in MEN2 in practical terms refers primarily to the screening for phaeochromocytoma (annual 24-h urinary catecholamines, CT, MIBG scanning) in MEN2A and 2B, and hyperparathyroidism (annual calcium, PTH – seen most with codon 634 mutations) in MEN2A. As regards the thyroid gland, all *RET* mutation carriers should undergo prophylactic total thyroidectomy to prevent the almost certain development of MTC. Thyroidectomy should be performed before the age of 6 months in MEN2B and before the age of 5 years in MEN2A, with MEN2B having a more aggressive course than MEN2A or FMTC. Table 10 lists the three categories of MTC risk based on *RET* mutation stratification. Following thyroidectomy, MTC surveillance can be achieved with fasting calcitonin values and, if elevated, a pentagastrin stimulation test. MRI scanning and where available pentavalent 99m Tc-dimercaptosuccinic acid (DMSA) nuclear medicine imaging (Warner & O'dorisio 2002) help localize disease recurrence. More than 90% of MTC cells express cholecystokinin B (CCK-B) receptors, and radio-labelled

**Table 9** MEN2 syndromes and penetrance. Adapted from Brandt *et al.* (2001).

MEN2 and variant syndromes	Features	Penetrance in adult carriers (%)
MEN2A (> 75% of all MEN2)	MTC Pheochromocytoma Parathyroid adenomas (variant also with cutaneous lichen amyloidosis or Hirschsprung's disease)	90% 50% 20–30%
FMTC MEN2B	MTC (variant also with Hirschsprung's disease) MTC Pheochromocytoma Intestinal and mucosal ganglioneuromatosis (with intestinal autonomic dysfunction leading to megacolon) Mafanoid habitus Decreased upper/lower body ratio Medullated corneal fibres	90% 90%

CCK-B ligands have also been used diagnostically (Behr & Behe 2002).

The management for tumour development in MEN2 has again been summarized in the consensus statement (Brandt *et al.* 2001). MTC conveys the main morbidity (when diagnosis is made after the opportunity for prophylactic thyroidectomy). Local spread is common and reoperation in the neck is indicated, particularly when there is no evidence of distant spread and for tumour-debulking to relieve calcitonin-induced symptoms such as diarrhoea. Unfortunately, MTC tends not to be responsive to either chemotherapy or radiotherapy. For MIBG-positive MTC, the option of targeted therapy (with radioactive MIBG) is an encouraging development, and more recently 90-yttrium-labelled CCK-B ligands have been shown to have therapeutic uses in MTC (Behr & Behe 2002), although limited by nephrotoxicity. The preferred therapy for unilateral adrenal pheochromocytoma is laparoscopic resection, following adequate pre-operative alpha- (with or without beta-) adrenergic blockade. Bilateral adrenal and extra-adrenal pheochromocytoma require open resection. Hyperparathyroidism is milder than in MEN1, but often more than one parathyroid gland is enlarged. The exact parathyroid procedure performed (e.g. subtotal, only enlarged glands) should be the same as in other disorders with multiple parathyroid tumours.

### Pheochromocytoma

Pheochromocytoma has already been briefly mentioned in the section on MEN2. Catecholamine-secreting tumours derive from neuroectoderm and arise from the adrenal medulla (pheochromocytoma) or from extra-adrenal neural crest. The cells of origin include chromaffin cells (pheochromocytoma and paraganglioma), ganglion cells (ganglioneuroma and ganglioneuroblastoma), sympathogone (sympathoblastoma) and sympathoblast (neuroblastoma) (Bouloux 2002). The annual incidence of catecholamine-secreting tumours is 2 to 8 per million population, although post-mortem studies indicate a higher incidence (up to 0.1%). Multiple and extra-adrenal tumours are seen in 35% of children compared with only 8% of adults, and criteria for malignancy are based more on size of tumour and metastatic spread than on histology; features suggestive of malignancy are seen 3 to 15 times more in paragangliomas than in pheochromocytoma (Bouloux 2002).

These tumours have attracted much interest in the literature recently, with the finding that 24% of nonsyndromic pheochromocytoma without a family history of the disease had a germline mutation in one of the familial conditions known to be associated with pheochromocytoma (Neumann *et al.* 2002) (see Table 11). The authors concluded that routine analysis for mutations of *RET*, *VHL*, *SDHD* and *SDHB* (the latter two genes encode the

**Table 10** Risk stratification of MEN2 mutations and MTC. Adapted from Brandt *et al.* (2001).

MTC risk category in MEN2	Mutated <i>RET</i> codon	Recommended age for thyroidectomy
Highest risk (level 3)	883, 918, 922	Within first 6 months of life (preferably within 1st month)
High risk (level 2)	611, 618, 620, 634	<age 5 years
Least risk (level 1)	609, 768, 790, 804, 891	<age 5 years/<age 10 years (little consensus in this group)

**Table 11** Familial syndromes associated with pheochromocytoma.

Familial syndromes associated with pheochromocytoma	Gene	Chromosome
MEN2	<i>RET</i>	10q11.2
von Hippel Lindau	<i>VHL</i>	3p26-p25
Neurofibromatosis type 1	<i>NF1</i>	17q11.2
Ataxia telangiectasia	<i>ATM</i>	11q22.3
Tuberose sclerosis	<i>TSC1, TSC2</i>	9q34, 16p13.3
Sturge–Weber	?	
Familial paragangliomas of the neck	<i>SDHD, SDHB</i>	11q23, 1p36.1-p35

mitochondrial complex II enzymes succinate dehydrogenase subunits D and B) should be performed in patients presenting with apparently sporadic pheochromocytoma.

## Conclusion

Neuroendocrine tumours form a diverse group of conditions with a large spectrum of clinical syndromes depending on the presence of secreted hormones. Their management is challenging, since morbidity is quite often related to the hypersecretion syndrome rather than tumour bulk. The advent of genetic screening has had a significant effect on patient management and counselling, and it is hoped that new technologies will allow for more precise patient risk stratification. The frequent expression of somatostatin receptors by these tumours allows for the highly beneficial use of somatostatin analogues, and most recently the introduction of targeted therapy. This is a very exciting development in the field, and further results are currently awaited.

## References

- Adams S & Baum RP 2000 Intraoperative use of gamma-detecting probes to localize neuroendocrine tumors. *Quarterly Journal of Nuclear Medicine* **44** 59–67.
- Ajani JA, Carrasco CH, Charnsangavej C, Samaan NA, Levin B & Wallace S 1988 Islet cell tumors metastatic to the liver: effective palliation by sequential hepatic artery embolization. *Annals of Internal Medicine* **108** 340–344.
- Aldridge MC & Williamson RCN 1993 Surgery of Endocrine Tumours of the Pancreas. In *Surgical Endocrinology*, pp 503–520. Eds J Lynn & SR Bloom. Oxford: Butterworth–Heinemann Ltd.
- Andrews JC, Walker SC, Ackermann RJ, Cotton LA, Ensminger WD & Shapiro B 1994 Hepatic radioembolization with yttrium-90 containing glass microspheres: preliminary results and clinical follow-up. *Journal of Nuclear Medicine* **35** 1637–1644.
- Arafah BM & Nasrallah MP 2001 Pituitary tumors: pathophysiology, clinical manifestations and management. *Endocrine-Related Cancer* **8** 287–305.
- Arnold R, Trautmann ME, Creutzfeldt W, Benning R, Benning M, Neuhaus C, Jurgensen R, Stein K, Schafer H, Bruns C & Dennler HJ 1996 Somatostatin analogue octreotide and inhibition of tumour growth in metastatic endocrine gastroenteropancreatic tumours. *Gut* **38** 430–438.
- Arnold R, Simon B & Wied M 2000 Treatment of neuroendocrine GEP tumours with somatostatin analogues: a review. *Digestion* **62** (Suppl 1) 84–91.
- Ashrafian H, Taylor-Robinson SD, Calam J & Playford RJ 2002 Once you start, you can't stop. *Lancet* **359** 226.
- Bardeesy N, Sinha M, Hezel AF, Signoretti S, Hathaway NA, Sharpless NE, Loda M, Carrasco DR & DePinho RA 2002 Loss of the *Lkb1* tumour suppressor provokes intestinal polyposis but resistance to transformation. *Nature* **419** 162–167.
- di Bartolomeo M, Bajetta E, Buzzoni R, Mariani L, Carnaghi C, Somma L, Zilembo N & di Leo A 1996 Clinical efficacy of octreotide in the treatment of metastatic neuroendocrine tumors. A study by the Italian Trials in Medical Oncology Group. *Cancer* **77** 402–408.
- Bechstein WO & Neuhaus P 1994 Liver transplantation for hepatic metastases of neuroendocrine tumors. *Annals of the New York Academy of Sciences* **733** 507–514.
- Behr TM & Behe MP 2002 Cholecystokinin-B/gastrin receptor-targeting peptides for staging and therapy of medullary thyroid cancer and other cholecystokinin-B receptor-expressing malignancies. *Seminars in Nuclear Medicine* **32** 97–109.
- Bergeron F, Leduc R & Day R 2000 Subtilase-like pro-protein convertases: from molecular specificity to therapeutic applications. *Journal of Molecular Endocrinology* **24** 1–22.
- Bilchik AJ, Sarantou T, Foshag LJ, Giuliano AE & Ramming KP 1997 Cryosurgical palliation of metastatic neuroendocrine tumors resistant to conventional therapy. *Surgery* **122** 1040–1047.
- Bouloux PG 2002 Pheochromocytomas and paragangliomas. In *Endocrinology Specialist Handbook*, pp 447–469. Eds K Meeran & S Robinson. London: Martin Dunitz Ltd.
- Brandi ML, Gagel RF, Angeli A, Bilezikian JP, Beck-Peccoz P, Bordi C, Conte-Devolx B, Falchetti A, Gheri RG, Libroia A, Lips CJ, Lombardi G, Mannelli M, Pacini F, Ponder BA, Raue F, Skogseid B, Tamburrano G, Thakker RV, Thompson NW, Tomassetti P, Tonelli F, Wells SA Jr & Marx SJ 2001 Guidelines for diagnosis and therapy of MEN type 1

- and type 2. *Journal Clinical Endocrinology and Metabolism* **86** 5658–5671.
- Buscaill L, Esteve JP, Saint-Laurent N, Bertrand V, Reisine T, O'Carroll AM, Bell GI, Schally AV, Vaysse N & Susini C 1995 Inhibition of cell proliferation by the somatostatin analogue RC-160 is mediated by somatostatin receptor subtypes SSTR2 and SSTR5 through different mechanisms. *PNAS* **92** 1580–1584.
- Bystrom C, Larsson C, Blomberg C, Sandelin K, Falkmer U, Skogseid B, Oberg K, Werner S & Nordenskjold M 1990 Localization of the MEN1 gene to a small region within chromosome 11q13 by deletion mapping in tumors. *PNAS* **87** 1968–1972.
- Calender A 2000 Molecular genetics of neuroendocrine tumors. *Digestion* **62** (Suppl 1) 3–18.
- Capella C, Heitz PU, Hofler H, Solcia E & Kloppel G 1994 Revised classification of neuroendocrine tumors of the lung, pancreas and gut. *Digestion* **55** (Suppl 3) 11–23.
- Carrasco CH, Chuang VP & Wallace S 1983 APUDomas metastatic to the liver: treatment by hepatic artery embolization. *Radiology* **149** 79–83.
- Chamberlain RS, Canes D, Brown KT, Saltz L, Jarnagin W, Fong Y & Blumgart LH 2000 Hepatic neuroendocrine metastases: does intervention alter outcomes? *Journal of the American College of Surgeons* **190** 432–445.
- Chen H, Hardacre JM, Uzar A, Cameron JL & Choti MA 1998 Isolated liver metastases from neuroendocrine tumors: does resection prolong survival? *Journal of the American College of Surgeons* **187** 88–92.
- Day R & Salzet M 2002 The neuroendocrine phenotype, cellular plasticity, and the search for genetic switches: redefining the diffuse neuroendocrine system. *Neuroendocrinology Letters* **23** 447–451.
- Doppman JL, Miller DL, Chang R, Maton PN, London JF, Gardner JD, Jensen RT & Norton JA 1990 Gastrinomas: localization by means of selective intraarterial injection of secretin. *Radiology* **174** 25–29.
- Doppman JL, Miller DL, Chang R, Shawker TH, Gorden P & Norton JA 1991 Insulinomas: localization with selective intraarterial injection of calcium. *Radiology* **178** 237–241.
- Emmert-Buck MR, Lubensky IA, Dong Q, Manickam P, Guru SC, Kester MB, Olufemi SE, Agarwal S, Burns AL, Spiegel AM, Collins FS, Marx SJ, Zhuang Z, Liotta LA, Chandrasekharappa SC & Debelenko LV 1997 Localization of the multiple endocrine neoplasia type I (MEN1) gene based on tumor loss of heterozygosity analysis. *Cancer Research* **57** 1855–1858.
- Eng C, Mulligan LM, Smith DP, Healey CS, Frilling A, Raue F, Neumann HP, Ponder MA & Ponder BA 1995 Low frequency of germline mutations in the RET proto-oncogene in patients with apparently sporadic medullary thyroid carcinoma. *Clinical Endocrinology* **43** 123–127.
- Eriksson B & Oberg K 1993 An update of the medical treatment of malignant endocrine pancreatic tumors. *Acta Oncology* **32** 203–208.
- Eriksson B, Arnberg H, Lindgren PG, Lorelius LE, Magnusson A, Lundqvist G, Skogseid B, Wide L, Wilander E & Oberg K 1990 Neuroendocrine pancreatic tumours: clinical presentation, biochemical and histopathological findings in 84 patients. *Journal of Internal Medicine* **228** 103–113.
- Eriksson B, Renstrup J, Imam H & Oberg K 1997 High-dose treatment with lanreotide of patients with advanced neuroendocrine gastrointestinal tumors: clinical and biological effects. *Annals of Oncology* **8** 1041–1044.
- Eriksson BK, Larsson EG, Skogseid BM, Lofberg AM, Lorelius LE & Oberg KE 1998 Liver embolizations of patients with malignant neuroendocrine gastrointestinal tumors. *Cancer* **83** 2293–2301.
- Eriksson B, Bergstrom M, Orlefors H, Sundin A, Oberg K & Langstrom B 2000 Use of PET in neuroendocrine tumors. In vivo applications and in vitro studies. *Quarterly Journal of Nuclear Medicine* **44** 68–76.
- Eriksson B, Bergstrom M, Sundin A, Juhlin C, Orlefors H, Oberg K & Langstrom B 2002 The role of PET in localization of neuroendocrine and adrenocortical tumors. *Annals of the New York Academy of Sciences* **970** 159–169.
- European Neuroendocrine Tumor Network (ENET) 2000 Role of somatostatin analogues in oncology. Round Table Discussion: Innsbruck, Austria, February 24–27 2000. *Digestion* **62** (Suppl 1) 98–107.
- Faiss S, Rath U, Mansmann U, Caird D, Clemens N, Riecken EO & Wiedenmann B 1999 Ultra-high-dose lanreotide treatment in patients with metastatic neuroendocrine gastroenteropancreatic tumors. *Digestion* **60** 469–476.
- Faiss S, Pape UF, Bohmig M, Dorffel Y, Mansmann U, Golder W, Riecken EO & Wiedenmann B 2003 Prospective, randomized, multicenter trial on the antiproliferative effect of lanreotide, interferon alfa, and their combination for therapy of metastatic neuroendocrine gastroenteropancreatic tumors - the International Lanreotide and Interferon Alfa Study Group. *Journal of Clinical Oncology* **21** 2689–2696.
- Fearon ER & Vogelstein B 1990 A genetic model for colorectal tumorigenesis. *Cell* **61** 759–767.
- Fedorak IJ, Ko TC, Gordon D, Flisak M & Prinz RA 1993 Localization of islet cell tumors of the pancreas: a review of current techniques. *Surgery* **113** 242–249.
- Fjallskog ML, Granberg DP, Welin SL, Eriksson C, Oberg KE, Janson ET & Eriksson BK 2001 Treatment with cisplatin and etoposide in patients with neuroendocrine tumors. *Cancer* **92** 1101–1107.
- Friesen SR 1987 Update on the diagnosis and treatment of rare neuroendocrine tumors. *Surgical Clinic of North America* **67** 379–393.
- Frucht H, Howard JM, Slaff JI, Wank SA, McCarthy DM, Maton PN, Vinayek R, Gardner JD & Jensen RT 1989 Secretin and calcium provocative tests in the Zollinger-Ellison syndrome. A prospective study. *Annals of Internal Medicine* **111** 713–722.
- Gilligan CJ, Lawton GP, Tang LH, West AB & Modlin IM 1995 Gastric carcinoid tumors: the biology and therapy of an enigmatic and controversial lesion. *American Journal of Gastroenterology* **90** 338–352.
- Glover JR, Shorvon PJ & Lees WR 1992 Endoscopic ultrasound for localisation of islet cell tumours. *Gut* **33** 108–110.
- Goldstone AP, Scott-Coombes DM & Lynn JA 1996 Surgical management of gastrointestinal endocrine tumours. *Baillieres Clinical Gastroenterology* **10** 707–736.

- Hamid QA, Bishop AE, Sikri KL, Varndell IM, Bloom SR & Polak JM 1986 Immunocytochemical characterization of 10 pancreatic tumours, associated with the glucagonoma syndrome, using antibodies to separate regions of the pro-glucagon molecule and other neuroendocrine markers. *Histopathology* **10** 119–133.
- de Herder WW & Lamberts SW 2002 Somatostatin and somatostatin analogues: diagnostic and therapeutic uses. *Current Opinion in Oncology* **14** 53–57.
- Herman JG, Latif F, Weng Y, Lerman MI, Zbar B, Liu S, Samid D, Duan DS, Gnarr JR, Linehan WM & Baylin SB 1994 Silencing of the VHL tumor-suppressor gene by DNA methylation in renal carcinoma. *PNAS* **91** 9700–9704.
- Jaeck D, Oussoultzoglou E, Bachellier P, Lemarque P, Weber JC, Nakano H & Wolf P 2001 Hepatic metastases of gastroenteropancreatic neuroendocrine tumors: safe hepatic surgery. *World Journal of Surgery* **25** 689–692.
- Jakobovitz O, Nass D, DeMarco L, Barbosa AJ, Simoni FB, Rechavi G & Friedman E 1996 Carcinoid tumors frequently display genetic abnormalities involving chromosome 11. *Journal of Clinical Endocrinology and Metabolism* **81** 3164–3167.
- Janson ET, Holmberg L, Stridsberg M, Eriksson B, Theodorsson E, Wilander E & Oberg K 1997 Carcinoid tumors: analysis of prognostic factors and survival in 301 patients from a referral center. *Annals of Oncology* **8** 685–690.
- Jensen RT 2001 Endocrine tumors of the gastrointestinal tract and pancreas. In *Harrison's Principles of Internal Medicine*, edn 15, pp 593–603. Eds E Braunwald, AS Fauci, DL Kasper, SL Hauser, DL Longo & JL Jameson. New York: McGraw-Hill.
- de Jong M, Bakker WH, Krenning EP, Breeman WA, van der Pluijm ME, Bernard BF, Visser TJ, Jermann E, Behe M, Powell P & Macke HR 1997 Yttrium-90 and indium-111 labelling, receptor binding and biodistribution of [DOTA<sup>0</sup>,D-Phe<sup>1</sup>,Tyr<sup>3</sup>]octreotide, a promising somatostatin analogue for radionuclide therapy. *European Journal of Nuclear Medicine* **24** 368–371.
- Kaltsas GA, Mukherjee JJ, Isidori A, Kola B, Plowman PN, Monson JP, Grossman AB & Besser GM 2002 Treatment of advanced neuroendocrine tumours using combination chemotherapy with lomustine and 5-fluorouracil. *Clinical Endocrinology* **57** 169–183.
- de Kerviler E, Cadiot G, Lebtahi R, Faraggi M, Le Guludec D & Mignon M 1994 Somatostatin receptor scintigraphy in forty-eight patients with the Zollinger-Ellison syndrome. GRESZE: Groupe d'Etude du Syndrome de Zollinger-Ellison. *European Journal of Nuclear Medicine* **21** 1191–1197.
- Kimura W, Kuroda A & Morioka Y 1991 Clinical pathology of endocrine tumors of the pancreas. Analysis of autopsy cases. *Digestive Diseases and Sciences* **36** 933–942.
- Kloppel G & Heitz PU 1988 Pancreatic endocrine tumors. *Pathology, Research and Practice* **183** 155–168.
- Kloppel G & Heitz PU 1994 Classification of normal and neoplastic neuroendocrine cells. *Annals of the New York Academy of Sciences* **733** 19–23.
- Knudson AG Jr 1971 Mutation and cancer: statistical study of retinoblastoma. *PNAS* **68** 820–823.
- Kouvaraki MA, Lee JE, Shapiro SE, Gagel RF, Sherman SI, Sellin RV, Cote GJ & Evans DB 2002 Genotype-phenotype analysis in multiple endocrine neoplasia type 1. *Archives in Surgery* **137** 641–647.
- Krenning EP, Kwekkeboom DJ, Bakker WH, Breeman WA, Kooij PP, Oei HY, van Hagen M, Postema PT, de Jong M, Reubi JC, Visser TJ, Reis AEM, Hofland LT, Koper JW & Lamberts SWJ 1993 Somatostatin receptor scintigraphy with [111In-DTPA-D-Phe<sup>1</sup>]- and [123I-Tyr<sup>3</sup>]octreotide: the Rotterdam experience with more than 1000 patients. *European Journal of Nuclear Medicine* **20** 716–731.
- Kwekkeboom DJ & Krenning EP 2002 Somatostatin receptor imaging. *Seminars in Nuclear Medicine* **32** 84–91.
- Kwekkeboom DJ, Bakker WH, Kam BL, Teunissen JJ, Kooij PP, de Herder WW, Feelders RA, Van Eijck CH, de Jong M, Srinivasan A, Erion JL & Krenning EP 2003 Treatment of patients with gastro-entero-pancreatic (GEP) tumours with the novel radiolabelled somatostatin analogue [(177)Lu-DOTA(0),Tyr(3)]octreotate. *European Journal of Nuclear Medicine and Molecular Imaging* **30** 417–422.
- Langley K 1994 The neuroendocrine concept today. *Annals of the New York Academy of Sciences* **733** 1–17.
- Larsson C, Skogseid B, Oberg K, Nakamura Y & Nordenskjold M 1988 Multiple endocrine neoplasia type 1 gene maps to chromosome 11 and is lost in insulinoma. *Nature* **332** 85–87.
- Lauffer JM, Zhang T & Modlin IM 1999 Review article: current status of gastrointestinal carcinoids. *Alimentary Pharmacology and Therapeutics* **13** 271–287.
- Le Douarin NM 1988 On the origin of pancreatic endocrine cells. *Cell* **53** 169–171.
- Lebtahi R, Cadiot G, Sarda L, Daou D, Faraggi M, Petegnief Y, Mignon M & Le Guludec D 1997 Clinical impact of somatostatin receptor scintigraphy in the management of patients with neuroendocrine gastroenteropancreatic tumors. *Journal of Nuclear Medicine* **38** 853–858.
- Legaspi A & Brennan MF 1988 Management of islet cell carcinoma. *Surgery* **104** 1018–1023.
- Leimer M, Kurtaran A, Smith-Jones P, Raderer M, Havlik E, Angelberger P, Vorbeck F, Niederle B, Herold C & Virgolini I 1998 Response to treatment with yttrium 90-DOTA-lanreotide of a patient with metastatic gastrinoma. *Journal of Nuclear Medicine* **39** 2090–2094.
- Lightdale CJ, Botet JF, Woodruff JM & Brennan MF 1991 Localization of endocrine tumors of the pancreas with endoscopic ultrasonography. *Cancer* **68** 1815–1820.
- Lubensky IA, Debelenko LV, Zhuang Z, Emmert-Buck MR, Dong Q, Chandrasekharappa S, Guru SC, Manickam P, Olufemi SE, Marx SJ, Spiegel AM, Collins FS & Liotta LA 1996 Allelic deletions on chromosome 11q13 in multiple tumors from individual MEN1 patients. *Cancer Research* **56** 5272–5278.
- McGuigan JE & Wolfe MM 1980 Secretin injection test in the diagnosis of gastrinoma. *Gastroenterology* **79** 1324–1331.
- McStay MK & Caplin ME 2002 Carcinoid tumour. *Minerva Medicine* **93** 389–401.
- Marx SJ, Agarwal SK, Kester MB, Heppner C, Kim YS, Emmert-Buck MR, Debelenko LV, Lubensky IA, Zhuang Z, Guru SC, Manickam P, Olufemi SE, Skarulis MC, Doppman JL, Alexander RH, Liotta LA, Collins FS,

- Chandrasekharappa SC, Spiegel AM & Burns AL 1998 Germline and somatic mutation of the gene for multiple endocrine neoplasia type 1 (MEN1). *Journal of Internal Medicine* **243** 447–453.
- Marx SJ, Agarwal SK, Kester MB, Heppner C, Kim YS, Skarulis MC, James LA, Goldsmith PK, Saggarr SK, Park SY, Spiegel AM, Burns AL, Debelenko LV, Zhuang Z, Lubensky IA, Liotta LA, Emmert-Buck MR, Guru SC, Manickam P, Crabtree J, Erdos MR, Collins FS & Chandrasekharappa SC 1999 Multiple endocrine neoplasia type 1: clinical and genetic features of the hereditary endocrine neoplasias. *Recent Progress in Hormone Research* **54** 397–438.
- Modlin IM & Sandor A 1997 An analysis of 8305 cases of carcinoid tumors. *Cancer* **79** 813–829.
- Modlin IM & Tang LH 1997 Approaches to the diagnosis of gut neuroendocrine tumors: the last word (today). *Gastroenterology* **112** 583–590.
- Modlin IM, Lye KD & Kidd M 2003 A 5-decade analysis of 13 715 carcinoid tumors. *Cancer* **97** 934–959.
- Moertel CG, Kvols LK, O'Connell MJ & Rubin J 1991 Treatment of neuroendocrine carcinomas with combined etoposide and cisplatin. Evidence of major therapeutic activity in the anaplastic variants of these neoplasms. *Cancer* **68** 227–232.
- Moertel CG, Lefkopoulo M, Lipsitz S, Hahn RG & Klaassen D 1992 Streptozocin-doxorubicin, streptozocin-fluorouracil or chlorozotocin in the treatment of advanced islet-cell carcinoma. *New England Journal of Medicine* **326** 519–523.
- Moertel CG, Johnson CM, McKusick MA, Martin JK Jr, Nagorney DM, Kvols LK, Rubin J & Kunselman S 1994 The management of patients with advanced carcinoid tumors and islet cell carcinomas. *Annals of Internal Medicine* **120** 302–309.
- Moller JE, Connolly HM, Rubin J, Seward JB, Modesto K & Pellikka PA 2003 Factors associated with progression of carcinoid heart disease. *New England Journal of Medicine* **348** 1005–1015.
- Neumann HP, Bausch B, McWhinney SR, Bender BU, Gimm O, Franke G, Schipper J, Klisch J, Althoefer C, Zerres K, Januszewicz A, Eng C, Smith WM, Munk R, Manz T, Glaesker S, Apel TW, Treier M, Reineke M, Walz MK, Hoang-Vu C, Brauckhoff M, Klein-Franke A, Klose P, Schmidt H, Maier-Woelfle M, Peczkowska M, Szmigielski C & Eng C 2002 Germ-line mutations in nonsyndromic pheochromocytoma. *New England Journal of Medicine* **346** 1459–1466.
- Norheim I, Theodorsson-Norheim E, Brodin E & Oberg K 1986 Tachykinins in carcinoid tumors: their use as a tumor marker and possible role in the carcinoid flush. *Journal of Clinical Endocrinology and Metabolism* **63** 605–612.
- Oberg K 2000 Interferon in the management of neuroendocrine GEP-tumors: a review. *Digestion* **62** (Suppl 1) 92–97.
- Oberg K & Eriksson B 1991 The role of interferons in the management of carcinoid tumors. *Acta Oncology* **30** 519–522.
- Oberg K & Skogseid B 1998 The ultimate biochemical diagnosis of endocrine pancreatic tumours in MEN-1. *Journal of Internal Medicine* **243** 471–476.
- Oberg K, Funa K & Alm G 1983 Effects of leukocyte interferon on clinical symptoms and hormone levels in patients with mid-gut carcinoid tumors and carcinoid syndrome. *New England Journal of Medicine* **309** 129–133.
- O'Shea D, Rohrer-Theurs AW, Lynn JA, Jackson JE & Bloom SR 1996 Localization of insulinomas by selective intraarterial calcium injection. *Journal of Clinical Endocrinology and Metabolism* **81** 1623–1627.
- Palazzo L, Roseau G & Salmeron M 1992 Endoscopic ultrasonography in the preoperative localization of pancreatic endocrine tumors. *Endoscopy* **24** (Suppl 1) 350–353.
- Pannett AA & Thakker RV 2001 Somatic mutations in MEN type 1 tumors, consistent with the Knudson 'two-hit' hypothesis. *Journal of Clinical Endocrinology and Metabolism* **86** 4371–4374.
- Patel YC & Srikant CB 1994 Subtype selectivity of peptide analogs for all five cloned human somatostatin receptors (hsstr 1-5). *Endocrinology* **135** 2814–2817.
- Pearse AG 1968 Common cytochemical and ultrastructural characteristics of cells producing polypeptide hormones (the APUD series) and their relevance to thyroid and ultimobranchial C cells and calcitonin. *Proceedings of the Royal Society of London. Series B: Biological Sciences* **170** 71–80.
- Pearse AG 1969 The cytochemistry and ultrastructure of polypeptide hormone-producing cells of the APUD series and the embryologic, physiologic and pathologic implications of the concept. *Journal of Histochemistry and Cytochemistry* **17** 303–313.
- Phillips TJ & Belknap JK 2002 Complex-trait genetics: emergence of multivariate strategies. *Nature Reviews. Neuroscience* **3** 478–485.
- Polak JM & Bloom SR 1979 The diffuse neuroendocrine system. Studies of this newly discovered controlling system in health and disease. *Journal of Histochemistry and Cytochemistry* **27** 1398–1400.
- Polak JM & Bloom SR 1986a Regulatory peptides of the gastrointestinal and respiratory tracts. *Archives Internationales de Pharmacodynamie et de Therapie* **280** 16–49.
- Polak JM & Bloom SR 1986b Somatostatin localization in tissues. *Scandinavian Journal of Gastroenterology* **119** (Suppl) 11–21.
- Prowse AH, Webster AR, Richards FM, Richard S, Olschwang S, Resche F, Affara NA & Maher ER 1997 Somatic inactivation of the VHL gene in Von Hippel-Lindau disease tumors. *American Journal of Human Genetics* **60** 765–771.
- Que FG, Nagorney DM, Batts KP, Linz LJ & Kvols LK 1995 Hepatic resection for metastatic neuroendocrine carcinomas. *American Journal of Surgery* **169** 36–42.
- Reisine T & Bell GI 1995 Molecular biology of somatostatin receptors. *Endocrine Reviews* **16** 427–442.
- Ricke J, Klose KJ, Mignon M, Oberg K & Wiedenmann B 2001 Standardisation of imaging in neuroendocrine tumours: results of a European Delphi process. *European Journal of Radiology* **37** 8–17.
- Rindi G, Capella C & Solcia E 1998 Cell biology, clinicopathological profile, and classification of gastroenteropancreatic endocrine tumors. *Journal of Molecular Medicine* **76** 413–420.
- Rosch T, Lightdale CJ, Botet JF, Boyce GA, Sivak MV Jr, Yasuda K, Heyder N, Palazzo L, Dancygier H, Schudziarra

- V & Lassen M 1992 Localization of pancreatic endocrine tumors by endoscopic ultrasonography. *New England Journal of Medicine* **326** 1721–1726.
- Rougier P & Mitry E 2000 Chemotherapy in the treatment of neuroendocrine malignant tumors. *Digestion* **62** (Suppl 1) 73–78.
- Ruszniewski P & Malka D 2000 Hepatic arterial chemoembolization in the management of advanced digestive endocrine tumors. *Digestion* **62** (Suppl 1) 79–83.
- Ruszniewski P, Amouyal P, Amouyal G, Grange JD, Mignon M, Bouche O & Bernades P 1995 Localization of gastrinomas by endoscopic ultrasonography in patients with Zollinger–Ellison syndrome. *Surgery* **117** 629–635.
- Sandler M & Snow P 1958 An atypical carcinoid tumour secreting 5-hydroxytryptophan. *Lancet* **1** 139.
- Sapin R 2003 Insulin assays: previously known and new analytical features. *Clinical Laboratory* **49** 113–121.
- Schindl M, Kaczirek K, Kaserer K & Niederle B 2000 Is the new classification of neuroendocrine pancreatic tumors of clinical help? *World Journal of Surgery* **24** 1312–1318.
- Sekiya K, Ghatei MA, Salahuddin MJ, Bishop AE, Hamid QA, Ibayashi H, Polak JM & Bloom SR 1989 Production of GAWK (chromogranin-B 420-493)-like immunoreactivity by endocrine tumors and its possible diagnostic value. *Journal of Clinical Investigation* **83** 1834–1842.
- Service FJ 1995 Hypoglycemic disorders. *New England Journal of Medicine* **332** 1144–1152.
- Service FJ & Natt N 2000 The prolonged fast. *Journal of Clinical Endocrinology and Metabolism* **85** 3973–3974.
- Shannon BA & Iacopetta BJ 2001 Methylation of the hMLH1, p16, and MDR1 genes in colorectal carcinoma: associations with clinicopathological features. *Cancer Letters* **167** 91–97.
- Snow P, Lennard-Jones J, Curzon G & Stacey RS 1955 Humoral effects of metastasising carcinoid tumours. *Lancet* **269** 1004–1009.
- Solcia E, Sessa F, Rindi G, Villani L, Riva C, Buffa R & Capella C 1990 Classification and histogenesis of gastroenteropancreatic endocrine tumours. *European Journal of Clinical Investigation* **20** (Suppl 1) 72–81.
- Solcia E, Kloppel G & Sobin LH 2000 World Health Organization International Histological Classification of Endocrine Tumours. Histological Typing of Endocrine Tumours 2nd edn.
- Stokes KR, Stuart K & Clouse ME 1993 Hepatic arterial chemoembolization for metastatic endocrine tumors. *Journal of Vascular and Interventional Radiology* **4** 341–345.
- Stridsberg M, Oberg K, Li Q, Engstrom U & Lundqvist G 1995 Measurements of chromogranin A, chromogranin B (secretogranin I), chromogranin C (secretogranin II) and pancreastatin in plasma and urine from patients with carcinoid tumours and endocrine pancreatic tumours. *Journal of Endocrinology* **144** 49–59.
- Taheri S & Meeran K 2002 Gut hormones and gut hormone tumours. In *Endocrinology Specialist Handbook*, pp 295–310. Eds K Meeran & S Robinson. London: Martin Dunitz Ltd.
- Taheri S, Ghatei MA & Bloom SR 2001 Gastrointestinal Hormones and Tumor Syndromes. In *Endocrinology*, 4th edn, pp 2547–2558. Eds LJ De Groot & JL Jameson. Philadelphia: WB Saunders.
- Tapia FJ, Polak JM, Barbosa AJ, Bloom SR, Marangos PJ, Dermody C & Pearse AG 1981 Neuron-specific enolase is produced by neuroendocrine tumours. *Lancet* **1** 808–811.
- Taupenot L, Harper KL & O'Connor DT 2003 The chromogranin-secretogranin family. *New England Journal of Medicine* **348** 1134–1149.
- Termanini B, Gibril F, Reynolds JC, Doppman JL, Chen CC, Stewart CA, Sutliff VE & Jensen RT 1997 Value of somatostatin receptor scintigraphy: a prospective study in gastrinoma of its effect on clinical management. *Gastroenterology* **112** 335–347.
- Thakker RV, Bouloux P, Wooding C, Chotai K, Broad PM, Spurr NK, Besser GM & O'Riordan JL 1989 Association of parathyroid tumors in multiple endocrine neoplasia type 1 with loss of alleles on chromosome 11. *New England Journal of Medicine* **321** 218–224.
- Thompson NW, Czako PF, Fritts LL, Bude R, Bansal R, Nostrant TT & Scheiman JM 1994 Role of endoscopic ultrasonography in the localization of insulinomas and gastrinomas. *Surgery* **116** 1131–1138.
- Tiensuu JE, Eriksson B, Oberg K, Skogseid B, Ohrvall U, Nilsson S & Westlin JE 1999 Treatment with high dose [(111)In-DTPA-D-PHE1]-octreotide in patients with neuroendocrine tumors - evaluation of therapeutic and toxic effects. *Acta Oncology* **38** 373–377.
- Todd JF & Bloom SR 2002 Insulinomas and hypoglycaemia. In *Oxford Textbook of Endocrinology and Diabetes*, Eds JAH Wass & SM Shalet. Oxford: Oxford University Press.
- Turner JJ, Wren AM, Jackson JE, Thakker RV & Meeran K 2002 Localization of gastrinomas by selective intra-arterial calcium injection. *Clinical Endocrinology* **57** 821–825.
- Vinik AI 2001 Carcinoid Tumors. In *Endocrinology*, 4th edn, pp 2533–2546. Eds LJ De Groot & JL Jameson. Philadelphia: WB Saunders.
- Virgolini I, Britton K, Buscombe J, Moncayo R, Paganelli G & Riva P 2002 In- and Y-DOTA-lanreotide: results and implications of the MAURITIUS trial. *Seminars in Nuclear Medicine* **32** 148–155.
- Wallace S, Ajani JA, Charnsangavej C, DuBrow R, Yang DJ, Chuang VP, Carrasco CH & Dodd GD Jr 1996 Carcinoid tumors: imaging procedures and interventional radiology. *World Journal of Surgery* **20** 147–156.
- Warner RR & O'dorisio TM 2002 Radiolabeled peptides in diagnosis and tumor imaging: clinical overview. *Seminars in Nuclear Medicine* **32** 79–83.
- Winkler H & Fischer-Colbrie R 1992 The chromogranins A and B: the first 25 years and future perspectives. *Neuroscience* **49** 497–528.
- Wood SM, Polak JM & Bloom SR 1983 Gut hormone secreting tumours. *Scandinavian Journal of Gastroenterology* **82** (Suppl) 165–179.
- Wulbrand U, Wied M, Zofel P, Goke B, Arnold R & Fehmann H 1998 Growth factor receptor expression in human gastroenteropancreatic neuroendocrine tumours. *European Journal of Clinical Investigation* **28** 1038–1049.
- Yao KA, Talamonti MS, Nemcek A, Angelos P, Chrisman H, Skarda J, Benson AB, Rao S & Joehl RJ 2001 Indications and results of liver resection and hepatic chemoembolization for

- metastatic gastrointestinal neuroendocrine tumors. *Surgery* **130** 677–682.
- Yasuda D, Iguchi H, Funakoshi A, Wakasugi H, Sekiya K, Misawa T, Tateishi K, Bloom SR & Nawata H 1993 Comparison of plasma pancreastatin and GAWK concentrations, presumed processing products of chromogranin A and B, in plasma of patients with pancreatic islet cell tumors. *Hormone and Metabolic Research* **25** 593–595.
- Yiangou Y, Williams SJ, Bishop AE, Polak JM & Bloom SR 1987 Peptide histidine-methionine immunoreactivity in plasma and tissue from patients with vasoactive intestinal peptide-secreting tumors and watery diarrhea syndrome. *Journal of Clinical Endocrinology and Metabolism* **64** 131–139.
- Zimmer T, Scherubl H, Faiss S, Stolzel U, Riecken EO & Wiedenmann B 2000 Endoscopic ultrasonography of neuroendocrine tumours. *Digestion* **62** (Suppl 1) 45–50.